

## Functional outcome of percutaneous fixation of medial malleolus fractures

Kamal M. S. Abdel-meguid<sup>1</sup>, Haytham A. Abdel-moneim<sup>1</sup>, Raed R. M. Ali<sup>1\*</sup>, Ahmed R. Fekry<sup>1</sup>

<sup>1</sup> Department of Orthopedic department, Faculty of Medicine, Fayoum University, Fayoum, Egypt.

\* Correspondence: Raed R. M. Ali, [rml1@efayoum.edu.eg](mailto:rml1@efayoum.edu.eg); Tel.: (002) 01027660739.

### Abstract

**Introduction:** The ankle is a large joint made up of three bones: The shin bone (tibia), The thinner bone (fibula), and (the talus); Ankle fractures in adults account for 10% of all fractures.

**Aim of the study:** To assess the efficacy, advantages, disadvantages, and functional outcome of percutaneous fixation in the management of medial malleolus fractures by using the American College of Foot and Ankle Surgeons (ACFAS)) scoring scale and finally follow-ups at the 3rd and 6th month postoperatively.

**Subjects and Methods:** Consents were obtained from 25 patients who sustained medial malleolus fractures. All were operated on via a percutaneous approach, using two 4 mm cancellous screws perpendicular to the fracture site. Sixteen patients had isolated medial malleolar fractures, while nine had bimalleolar fractures. The ankle-functional outcome of all patients was assessed using the (ACFAS) scoring scale after three and six months postoperatively.

**Results:** The mean duration of fracture union was (9.84±4.5) weeks and ranged between 6-24 weeks. The mean ACFAS score after three months of intervention was (78.32±9.5), which increased to (86.32±9.2) after six months.

**Conclusion:** The concept of the periosteal entrapment at the site of the medial malleolus fracture, being the main factor of non-union, didn't show any impact on the union of the fracture. When using our closed technique, after six months of postoperative follow-up, the final results of our study with regard to ACFAS scores were satisfactory and were almost the same for all patients.

**Keywords:** Ankle; Orthopedic surgery; percutaneous cannulated compression screw fixation

### 1. Introduction

The ankle joint complex is comprised of the lower leg and foot, and it forms the kinetic linkage allowing the lower limb to interact with the ground. The ankle's bony and ligamentous structure enables it to function with high stability [1]. Ankle fractures in adults are common injuries, accounting for 10% of all fractures. Their incidence had increased since the 1950s with an overall incidence of

168.7/100,000 person-years. Population aging, increasing obesity prevalence, and more widespread participation in sports activities are the major causes. The mean age of fracture was reported to be 41 years old. Ankle fractures are slightly more frequent in men than in women, 53% against 47%, respectively [2]. The main goals of fracture management are anatomic reduction of the fracture and protection of the

soft tissue envelope. Stable fractures, where the alignment of the ankle joint is preserved, rarely need surgery. Unstable fractures typically require closed or open reduction and internal fixation [3]. It is crucial to choose a proper treatment method for patients' rehabilitation post-fracture. Surgical treatment is the applicable clinical method. Conventional open reduction and internal fixation are common treatments for ankle fractures. It allows complete exposure, simple operation, effective minimizing of the fracture site, and good fixation. Therefore, exploring the best surgical method is still the hotspot of studies on ankle fractures [4]. However, open reduction and

internal fixation results in surgical trauma and a high rate of complications, the percutaneous cannulated compression screw fixation is an effective fixation method for limb fractures and an emerging internal fixation in recent years. Due to its small trauma and other advantages, it is widely used in clinical practice.

Therefore, the current study aimed to assess the efficacy, advantages, disadvantages, and functional outcome of percutaneous fixation in the management of medial malleolus fractures by using the American College of Foot and Ankle Surgeons (ACFAS)) scoring scale and finally follow-ups at the 3rd and 6th month postoperatively.

## 2. Subjects and methods

### 2.1. Study design

A prospective case series study of functional outcome of percutaneous fixation of medial malleolus fractures. That study was conducted by the orthopedic department at Fayoum University hospital.

### 2.2. Subjects

Twenty-five patients were involved in the study.

### 2.3. Inclusion criteria:

Any fracture of medial malleolus with the following criteria were included in the study, such as, the closed medial malleolus fractures either unimalleolar, bimalleolar, or trimalleolar fractures.

### 2.4. Exclusion criteria

- Pediatric patients less than 15 years old.
- Associated Pilon fracture.
- Revision cases and open fractures.
- Infected and Comminuted fractures.

### 2.5. Preoperative Assessment

#### 2.5.1. Clinical assessment

Informed consent was taken from all patients. Surgery was performed on the same day of admission if the skin condition allowed, and for patients who presented with moderate or severe ankle edema, anti-edematous measures and medications were prescribed and their surgeries were postponed till the skin condition improved.

#### 2.5.2. Radiological assessment

An anteroposterior (A-P) view, mortise view, and lateral view (**Figure 1A**) for the injured ankle is ordered to adequately evaluate the ankle fracture, degree of displacement.

### 2.6. Surgical techniques

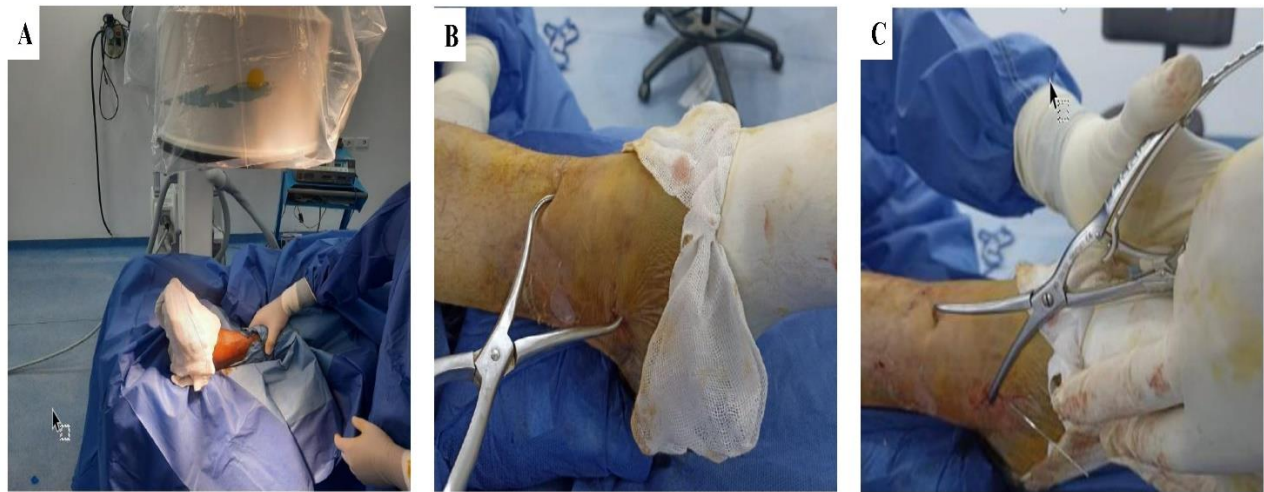
**Anesthesia:** Surgery was done under appropriate anesthesia.

**Patient position:** The patient was placed on the radiolucent operating table in the supine position (**Figure 1A**).

**Reduction of the fracture:** With the patients under anesthesia, manual traction reduction was performed to the fractured side under the guidance of a C-arm fluoroscope. The

reduction was held with pointed reduction forceps (**Figure 1**), perpendicular to the fracture

planes, good reduction of the fractures was confirmed by a C-arm device.

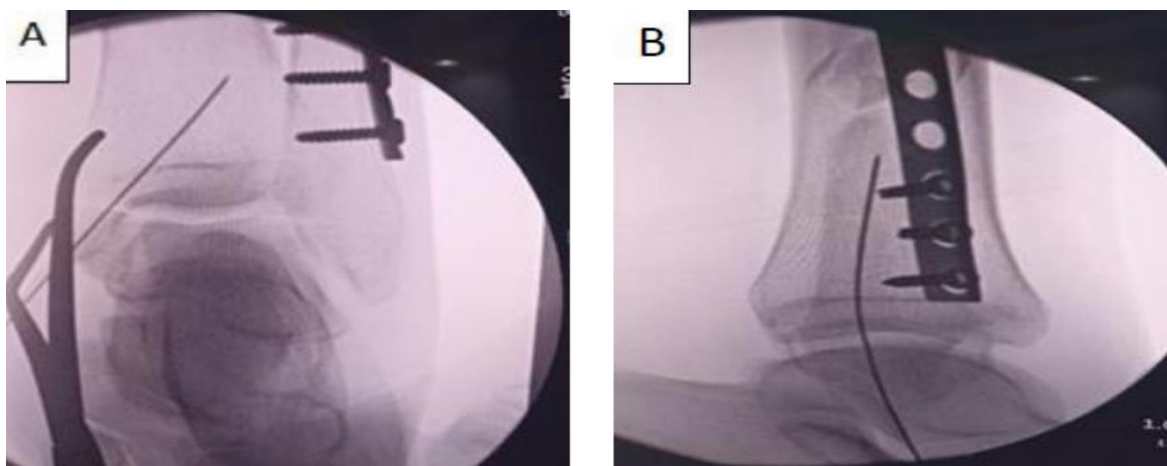


**Figure 1: Surgical techniques.** A) Supine position of the patient on a radiolucent table to allow the use of C-ARM image intensifier, B) &C) Showing closed reduction using pointed reduction forceps.

### 2.7. Percutaneous fixation of the fracture

After reduction of the articular surface in unimalleolar fracture of the medial malleolus and tow cannulated, partially threaded 4 mm screws were inserted to fix the fracture under the guidance of the image intensifier without the use

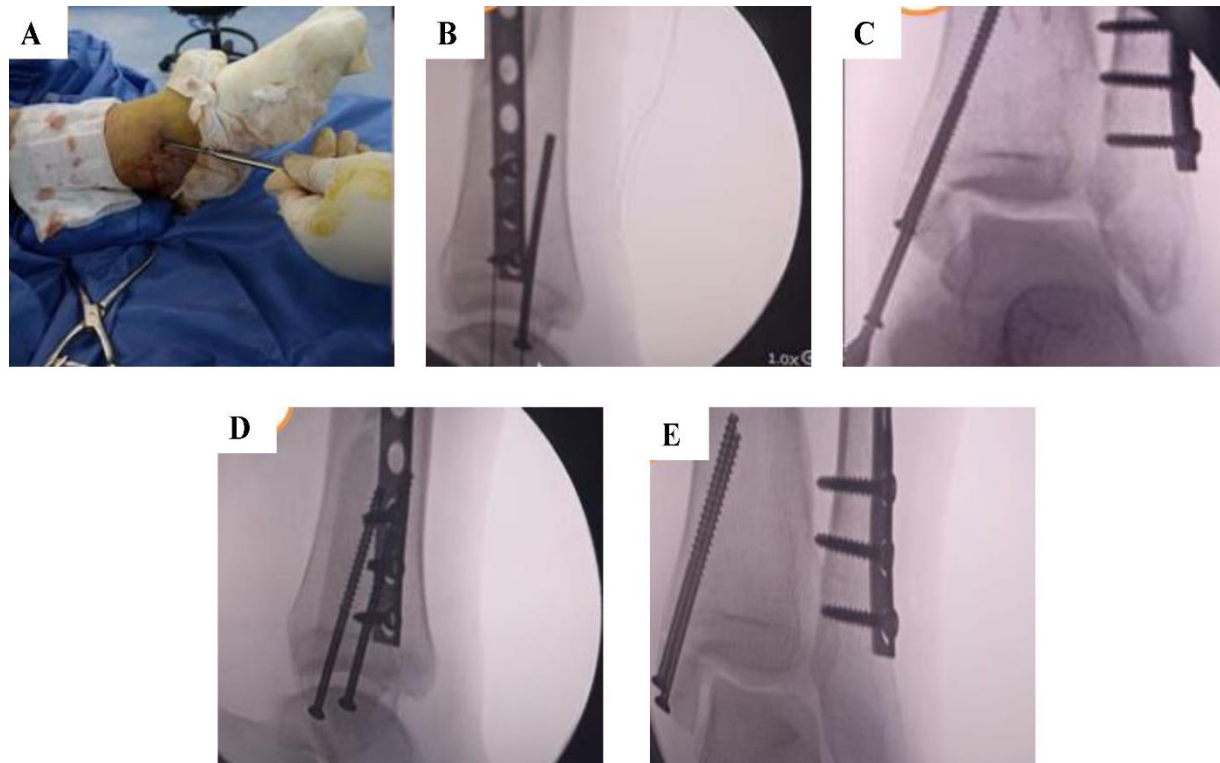
of washers. After countersinking the screw heads, to make them less prominent, the incision was sutured in layers. Compressive bandaging, concomitant with external plaster casting (or slab), was applied (**Figure 2**).



**Figure 2: Showing insertion guide -wire at the start of fixation.** A) insertion guide wire in anteroposterior view, B) inserting guide wire in lateral view.

If there was a bimalleolar fracture, the lateral malleolus was reduced and fixed first,

followed by reduction and fixation of the medial malleolus (Figure 3).



**Figure 3: The steps of inserting cannulated screws of medial malleolus fractures.** A) The inserting guide of 4 mm cannulated screw, B) A 4 mm cannulated screw in lateral view, C) Inserting the second 4 mm cannulated screw in anteroposterior view, D) lateral view of the ankle joint after fixation, E) Anteroposterior view of the ankle joint after fixation.

### 2.8. Postoperative care and follow-up

- Immediately after surgery, a plaster splint was applied as external support for the purpose of pain control.
- Anteroposterior, lateral, and mortise view x-rays of the ankle were done to evaluate fracture reduction and fixation.
- Knee exercises were commenced on 1st postoperative day. The plaster splint was removed after four weeks for unimalleolar fractures and six weeks for bimalleolar fractures. After that, weight-bearing started

after six weeks in unimalleolar fractures and eight weeks in bimalleolar fractures.

- The ankle functional outcome of all patients was assessed by using the American College of Foot & Ankle Surgeons (ACFAS) scoring scale after three and six months postoperatively. Scores ranged from 1-100 points, with more than 90 points indicating excellent outcomes, 75-89 points indicating good outcomes, 60-74 points indicating fair outcomes, and less than 60 points indicating poor outcomes [5].

### 2.9. Statistical Analysis

Data was collected and coded to facilitate data manipulation and double-entered into Microsoft Access. Data analysis was performed using the Statistical Package of Social Science (SPSS) software version 22 in windows 7 (SPSS Inc., Chicago, IL, USA). Simple descriptive analysis in the form of numbers and percentages of qualitative data, and arithmetic means as central tendency measurement, standard deviations as a measure of the dispersion of quantitative parametric data. Quantitative data included in the study was first tested for normality by the One-Sample

Kolmogorov-Smirnov test in each study group, followed by selected inferential statistic tests.

Independent samples test was used to compare quantitative measures between two independent groups. For quantitative nonparametric data, The Mann-Whitney test was used to compare two independent groups. For qualitative data. The Chi-square test was used to compare two more two qualitative groups. A Bivariate Pearson correlation test was used to test the association between variables. The results were considered statistically significant at  $P<0.05$ .

### 3. Results

#### 3.1. Descriptive analysis

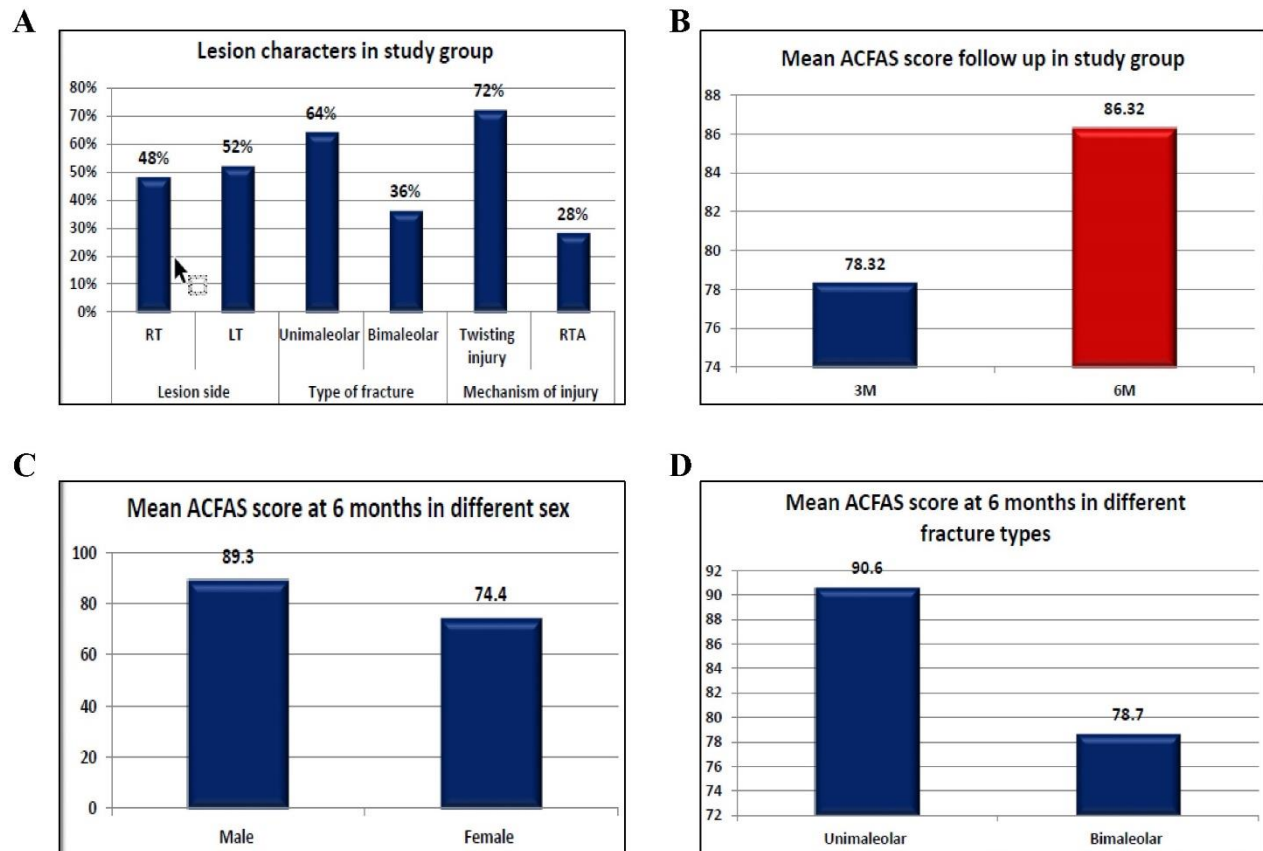
Twenty-five patients participated in this study. The age of our patients ranged from 17 and 70 years with a mean age of  $(36\pm14.2)$  years. Twenty (80%) of them were males, while five (20%) were females. 12 (48%) patients had fractures on the right side, while 13(52%) were on the left side. With regards to types of fracture, 16 (64%) had unimalleolar, while nine (36%) were bimalleolar. 18 (72%) cases were injured due to twisting injury, but seven (28%) were due to Road traffic accidents (RTA) (**Figure 4**).

In our study, the mean interval between the fracture date and the surgery was  $(7.04\pm6.2)$  days. The mean start ROM was at  $(4.72\pm0.98)$  weeks. Mean full weight

bearing was at  $(6.72\pm0.98)$  weeks (**Table 1**). The mean ACFAS score after three months of intervention among the study group was  $(78.32\pm9.5)$ , and it increased to  $(86.32\pm9.2)$  after six months, with a  $P<0.001$  (**Table 2**).

The study showed a statistically significant increase in ACFAS with  $P<0.001$  after six months of postoperative follow-up, which indicates improvement of the functional outcomes of the ankle joint after this period.

The mean duration of fracture union was  $(9.84\pm4.5)$  weeks, ranging between 6-24 weeks, and the mean radiation duration was  $(1.08\pm0.28)$ , and took between 1-2 minutes.



**Figure 4: Statistical analysis of the study results.** A) Frequency of different lesion characters among the study group, B) The mean ACFAS score follow-up among the study group, C) The mean ACFAS score at six months in different sex, D) The mean ACFAS score at six months in different fracture patterns, bimalleolar fractures, or females with unimalleolar or bimalleolar fractures.

**Table 1:** Frequency of different lesion characters among the study group.

Variables	Preoperative characters	
	Mean $\pm$ SD	Range
Interval between fracture and surgery (days)	7.04 $\pm$ 6.2	1-27
Start ROM (weeks)	4.72 $\pm$ 0.98	4-6
Full weight-bearing (weeks)	6.72 $\pm$ 0.98	6-8

*SD: standard deviation, ROM: range of motion rupture of membranes.*

**Table 2:** Comparison of ACFAS scores follow-ups among the study population.

Variables	ACFAS score	
	Mean $\pm$ SD	Range
After 3 months	78.32 $\pm$ 9.5	52-91
After 6 months	86.32 $\pm$ 9.2	60-97
<i>P-value</i>	< 0.001	

*SD: standard deviation.*

Regarding the effect of fracture pattern and patient ages on ACFAS scores, there was a statistically significant higher mean of ACFAS

scores at six months, both among males and cases with unimalleolar fracture with  $P<0.05$  (Table 3).

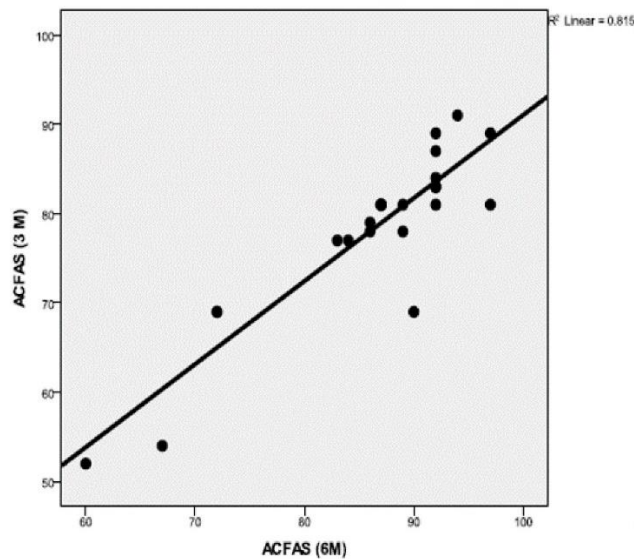
**Table 3:** Frequency of different lesion characters among the study group.

Variables (n=25)		ACFAS score (6m)	<i>P-value</i>
Sex	Male	89.3 $\pm$ 5.6	0.003*
	Female	74.4 $\pm$ 11.8	
Type of fracture	Unimalleolar	90.6 $\pm$ 3.7	0.001*
	Bimalleolar	78.7 $\pm$ 11.2	
Mechanism of injury	Twisting injury	85.6 $\pm$ 9.6	0.5
	RTA	88.3 $\pm$ 8.3	

Furthermore, the results showed that according to the ACFAS scores during the follow-up period, there was a statistically significant positive correlation between ACFAS

scores at 3-6 months ( $P<0.05$ ). That suggested the increase in ACFAS score at three months might be associated with an increase in ACFAS score at six months, as shown in (Figure 5).





**Figure 5: Correlation between ACFAS score at 3-6 months.**

### 3.2. Complications

The postoperative complications developed as delayed wound healing improved by repeated dressing in one (4%) case. Two (8%) cases sustained delayed fracture union, and developed complete union at ten months of their

operations, while an assessment of fracture union was done by the radiograph according to the RUST score. One (4%) case had a superficial skin infection in a diabetic patient, which didn't need debridement.

## 4. Discussion

The aim of the study was to assess the efficacy, advantages, disadvantages, and functional outcome of percutaneous fixation in the management of medial malleolus fractures by using the ACFAS scoring scale at the final follow-up; in the 3rd and 6th month after surgery. According to ACFAS scores, we reached satisfactory results in ankle functional outcomes. The mean ACFAS score after three months of intervention was ( $78.32 \pm 9.5$ ), which increased to ( $86.32 \pm 9.2$ ) after six months ( $P < 0.001$ ).

We preferred to use the ACFAS as a tool for assessing the functional outcome of our study. ACFAS developed a clinical tool to

assess objective and subjective parameters, giving the patient a final score, which is useful in the follow-up period and has an important role in the clinical studies about foot and ankle conditions.

According to these scores, out of 25 patients in our study, 11 reached excellent post-operative ankle recovery, while ten patients reached good results (84%) and four patients reached fair results at the 6th-month follow-up.

Similar to our results, Li *et al.* (2018), in their comparative study between fifty patients with medial malleolus fractures treated by percutaneous fixation and fifty patients treated by ORIF, found that 35 patients reached



excellent post-operative ankle recovery, nine patients reached good results in the percutaneous group (88%), while in the ORIF group only nineteen patients reached an excellent post-operative ankle recovery and seventeen patients reached good recovery (72%) [6].

Bulut *et al.* (2018) also reached satisfactory results in ankle functional outcomes in their study on 31 patients with ankle fractures [7]. The patients treated with Herbert screw fixatives achieved the highest ACFAS score (96), while those treated with the cancellous lag screws or fixated by tension band wiring achieved a score of 93 [7].

Regarding the fracture union in our study, all patients were united with a mean duration of fracture union of  $9.84 \pm 4.5$  weeks, ranging between (6 and 24) weeks. Our results were comparable to those of Li *et al.* (2018), who had treated fifty patients by percutaneous fixation of medial malleolus fractures and achieved union in  $10.8 \pm 2.4$  weeks [6]. In contrast, the duration of union was  $14.4 \pm 2.8$  weeks in the group treated by ORIF [5], thereby, we could deduce that periosteal stripping and surrounding soft tissue injury that occurs during ORIF could affect the blood supply and cause delayed bone healing. That is an important issue that should be considered during decision-making on ankle fractures.

Bulut *et al.* (2018) were able to achieve earlier union with an average of (8.8 weeks) in the group of patients treated with Herbert screws, which was nearly similar to our findings [7]. The other groups treated by lag screws or tension band wiring had a mean duration of the union of 10 and 9.8 weeks, respectively. Thus, the average union time for these lag screw groups was almost the same as ours.

In the comparative study conducted by Matson *et al.* (2017), forty patients with ankle fractures were treated by percutaneous fixation

and achieved a mean duration of union within  $10 \pm 4$  weeks, which is delayed in comparison to our results [8]. In the previous study, another group of 144 patients were treated by tension band wiring and achieved a mean duration of union within  $10 \pm 11$  weeks [8]. In comparison to the results of Matson *et al.* (2017), our results revealed that the union rate was faster. The results agreed with the study conducted by Du *et al.* (2011), in which 19 patients with ankle fractures were treated by percutaneous fixation and achieved union with an average of 12.8 weeks with a range of 10.4: 15.2 weeks [9].

In the current study, we found that the type of ankle fracture had a great effect on the functional outcome post-operatively; we deduce that after six months of follow-up the ACFAS scores of males with unimalleolar fractures were higher than those with bimalleolar fractures or females with unimalleolar or bimalleolar fractures. In this series, we used percutaneous fixation of medial malleolus by 4 mm cannulated screws, as a tool of fixation in our study group, because of the multiple advantages of this technique that include minimal soft tissue injury, sparing the saphenous vein and nerve, small post-operative scar, short hospital stays, and satisfactory post-operative functional outcome of the ankle joint. Regarding the method and the tool of fixation, Bulut *et al.* (2018) reported similar findings, where they found that the best results were obtained with patients treated with Herbert screws, with regards to high ACFAS scores, duration of union, and post-operative medial side irritation of the ankle. Despite the lower cost of our screws in comparison to the Herbert's, we were able to achieve almost the same results [7].

In our study, we intended to perform countersinking of screw heads without washers to avoid soft tissue irritation, and we found that it doesn't affect the stability of fixation. Despite the advantages of the percutaneous technique,

we recorded some post-operative complications. Two patients reported either a superficial skin infection or delayed wound healing, while another two experienced delayed fracture union till the 10th month of follow-up. Non-unions were not observed, and neither did any patient require hardware removal in the first 12 months of follow-up. Similarly, Li *et al.* (2018), documented post-operative complications in the group fixated percutaneously such as hardware loosening and ankle joint stiffness [6]. In the group that underwent ORIF, they noticed the occurrence of infection, loosening of hardware, and joint stiffness, however, most of that complications did not occur in our study, although they used the same fixation method.

In the study conducted by Georgiadis *et al.* (1995), 40 patients with displaced medial malleolar fractures were treated with modified tension band wiring [10]. Neither loss of reduction, tension band breakage, nor screw loosening was reported. Five patients experienced small degrees of subsequent K-wires migration. Slight radiographic prominence of the K-wires was typically non-palpable and did not necessarily correlate with clinical symptoms, whereas low anchoring screw placement was more likely to be painful. They reported cellulitis in the post-operative period and early post-traumatic arthritis, despite, it wasn't reported in our study due to the minimally invasive intervention of the percutaneous fixation.

In summary, our results in accordance with the abovementioned studies revealed that the percutaneous fixation method of treatment of

the medial malleolar fractures had many advantages over other fixation methods. That included decreasing soft tissue problems, recording a high union rate, and satisfactory ACFAS scores, with the subsequent achievement of satisfactory functional outcomes. Small sample sizes, short follow-up periods, and noncompliance of some patients during it were the main limitations of our study.

## Conclusions

The percutaneous fixation by partially threaded cannulated screws for the treatment of medial malleolar fractures decreases hospital stay and soft tissue problems due to its less invasive nature and less post-operative irritation, with the subsequent achievement of satisfactory functional and radiological outcomes. The periosteal entrapment at the site of fracture of the medial malleolus, which was believed to be the main factor of non-union, didn't show any impact on fracture union when using our closed technique. After six months of postoperative follow-up, the final results in our study with regards to ACFAS scores were satisfactory and were almost the same for all patients.

**Funding:** This research is not funded.

**Ethical Approval Statement:** The protocol was approved by the Ethical Committee of Fayoum Faculty of Medicine, Fayoum, Egypt.

**Informed Consent Statement:** Written informed consents were obtained from all patients.

**Conflicts of Interest:** All authors declare no conflict of interest.

## References

1. Brockett CL, Chapman GJ. Biomechanics of the ankle. *Orthop Trauma*. 2016;30(3):232-8. doi: 10.1016/j.mpmorth.2016.04.015.
2. Jiang L, Wu J, Li M, Liu X, Luo C, Qu X. Cannulated screw and Kirschner fixation for the treatment of medial and lateral malleolar epiphyseal fractures in children: a

- retrospective study of 36 cases. *J Orthop Surg Res.* 2019;14(1):254. doi: 10.1186/s13018-019-1287-6.
3. Brockett CL, Chapman GJ. Biomechanics of the ankle. *Orthop Trauma.* 2016;30(3):232-8. doi: 10.1016/j.mporth.2016.04.015.
  4. Liodaki E, Kisch T, Wenzel E, Mailänder P, Stang F. Percutaneous Cannulated Compression Screw Osteosynthesis in Phalanx Fractures: The Surgical Technique, the Indications, and the Results. *Eplasty.* 2017;17:e8.
  5. Thomas JL, Christensen JC, Mendicino RW, Schuberth JM, Weil LS Sr, Zlotoff HJ, et al. ACFAS Scoring Scale user guide. *J Foot Ankle Surg.* 2005;44(5):316-35. doi: 10.1053/j.jfas.2005.07.012.
  6. Li C, Peng M, Lin G, Chen W, Wang W. Percutaneous compression cannulated screws of medial malleolus fractures. *Int J Clin Exp Med* 2018;11(3):2489-94.
  7. Bulut T, Gursoy M. Isolated Medial Malleolus Fractures: Conventional Techniques Versus Headless Compression Screw Fixation. *J Foot Ankle Surg.* 2018;57(3):552-6. doi: 10.1053/j.jfas.2017.12.005.
  8. Matson AP, Barchick SR, Adams SB. Comparison of Open Reduction and Internal Fixation Versus Closed Reduction and Percutaneous Fixation for Medial Malleolus Fractures. *J Am Acad Orthop Surg Glob Res Rev.* 2017;1(8):e048. doi: 10.5435/JAAOSGlobal-D-17-00048.
  9. Du H, Tian XX, Li TS, Chu JJ, Xiong MY, Wang JS, et al. [Treatment of medial malleolus fractures with closed reduction and percutaneous internal fixation]. *Zhongguo Gu Shang.* 2011;24(9):788-90. Chinese.
  10. Georgiadis GM, White DB. Modified tension band wiring of medial malleolar ankle fractures. *Foot Ankle Int.* 1995;16(2):64-8. doi: 10.1177/107110079501600202.